Subtemporal Extradural Approach For Superior Semicircular Canal Dehiscence: Results In Three Consecutive Patients

Sarah Hendrickx[1], Abdulhamid Ciçek[1], Jeroen Cortier[1], Glen Forton[2], Pieterjan Leupe[2] , Olivier Van Damme[1], Tim Couvreur[1] and Dimitri Vanhauwaert[1]

Department of Neurosurgery[1] and Department of Otolaryngology, Head and Neck Surgery[2], AZ Delta, Roeselare, Belgium

Introduction: Superior semicircular canal dehiscence (SSCD) or Minor´s syndrome is a rare disorder. Other otological pathology, in particular otosclerosis, can mimic this pathology, The five most characteristic symptoms are vertigo, nausea, nystagmus induced by sound (Tullio Phenomenon) or pressure (Hennebert´s Sign), pulsatile tinnitus, conductive hearing loss and autophony. These symptoms can be explained by the "third window" theory. Other common complaints such as vertigo by head movement, dizziness, instability, aural fullness and hearing loss are not specific for SSCD. Audiograms show typically low frequency conductive hearing loss. Computed tomography of the temporal bone is essential in diagnosing SSCD. Different non-surgical and surgical treatment options are previously described. Minimal symptoms or solitary hearing loss should be treated preferably non-surgically. Surgery appears to be most successful for vestibular symptoms and autophony. Three major techniques are described: round window reinforcement, transmastoid semicircular canal occlusion and subtemporal extradural resurfacing by craniotomy.

Methods: Three patients with severe, disabling symptoms of unilateral SSCD were operated. A subtemporal extradural approach was performed in each patient with covering the SSCD by bone and a tensor fascia latae plasty.

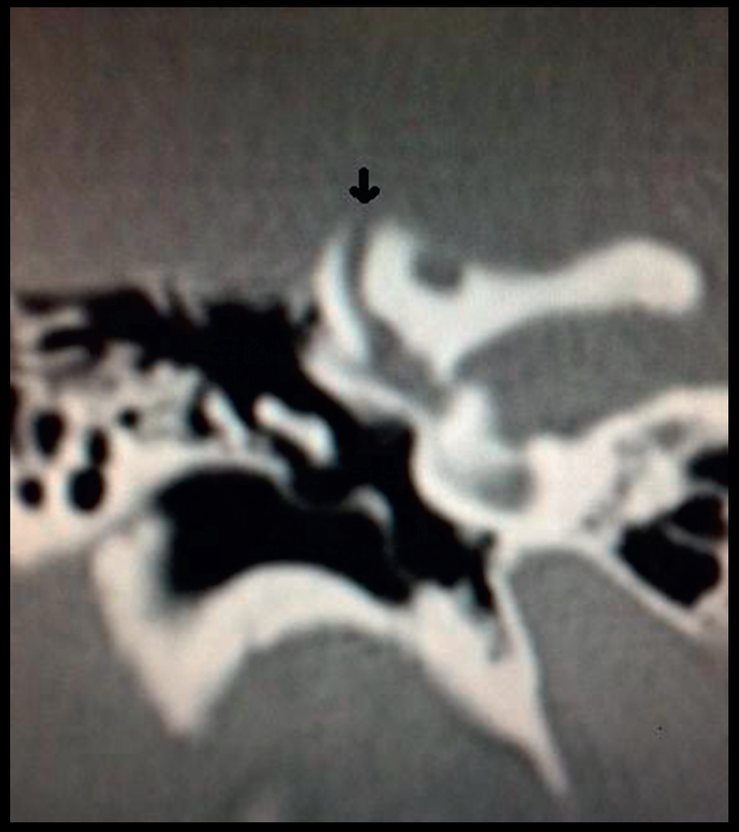

Figure 1: Preoperative Computed Tomography image of the right temporal bone. The arrow on the image shows the absence of bony coverage of the Superior Semicircular Canal.

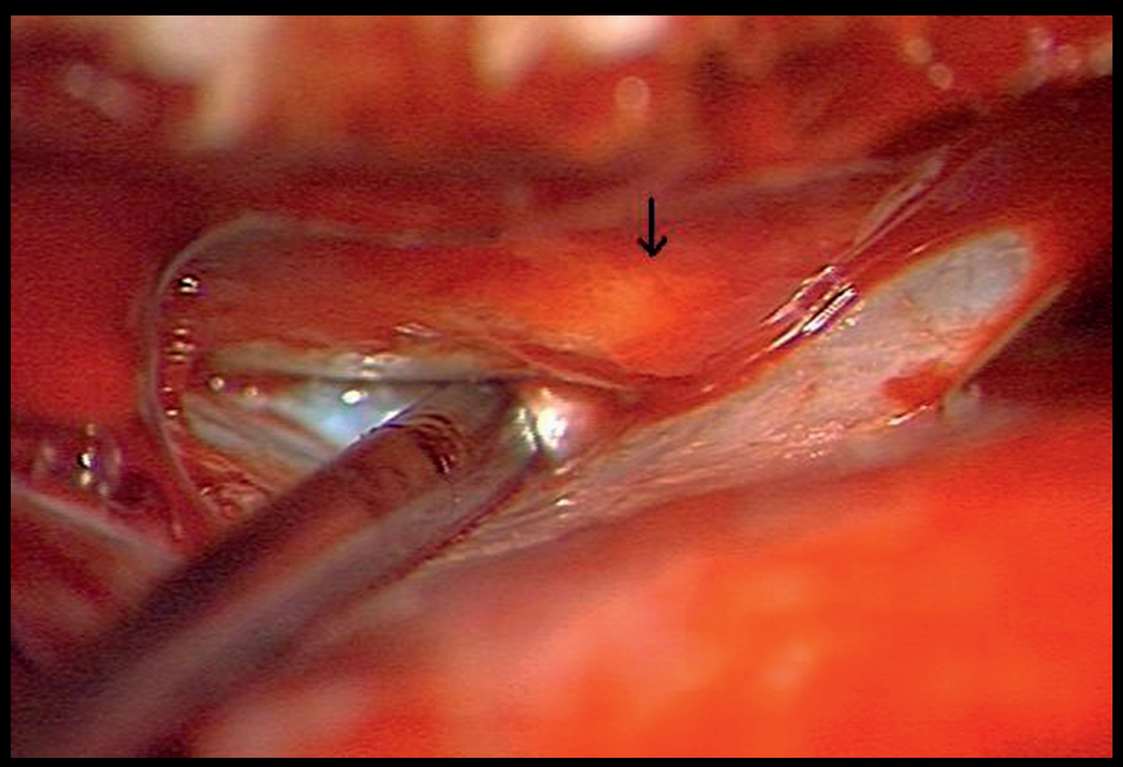

Figure 2: Intraoperative microscopic view of the Eminentia Arcuata with dehiscence of the Superior Semicircular Canal.

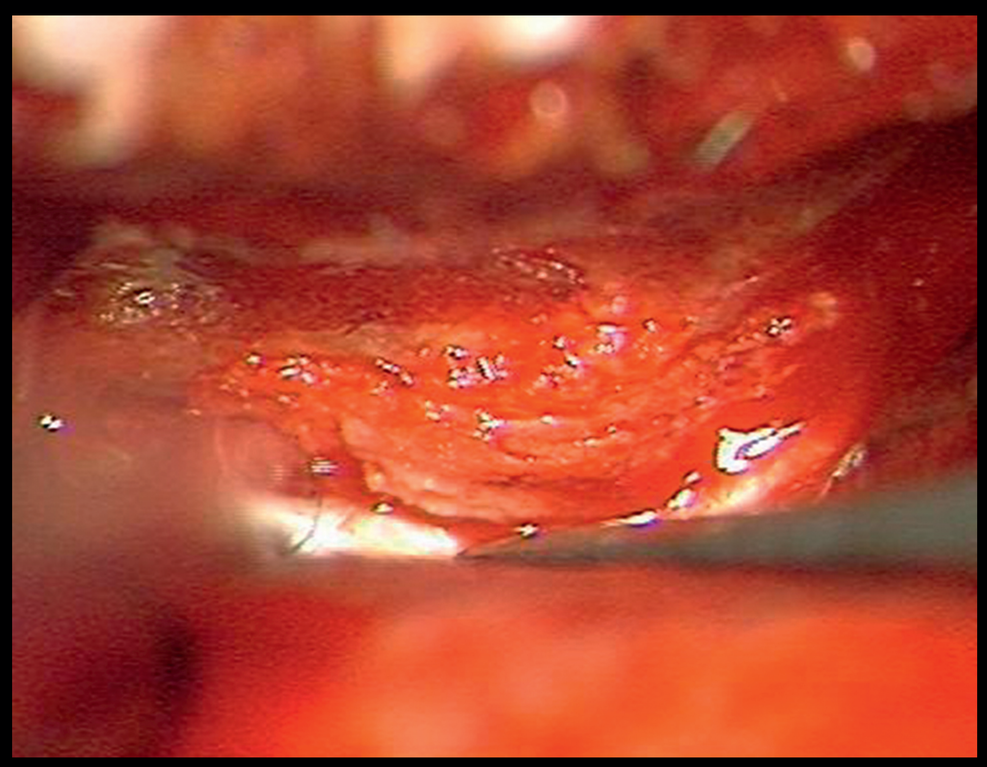

Figure 3: Intraoperative microscopic view of the Eminentia Arcuata showing coverage of the Superior Semicircular Canal by bone and tensor fascia latae plasty.

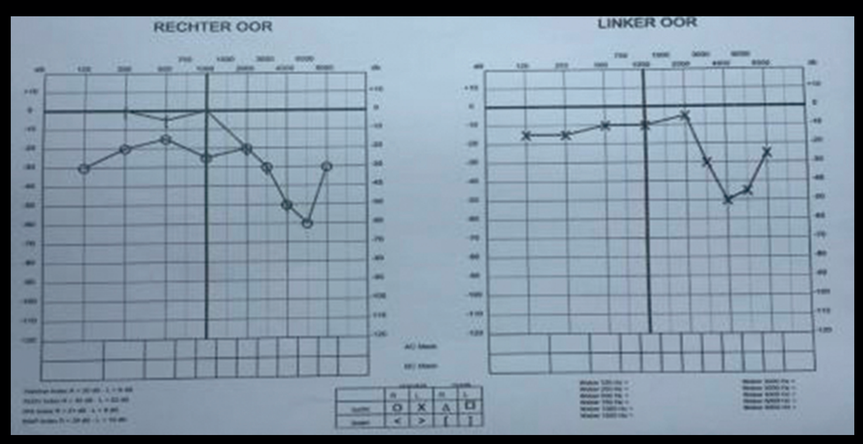

Figure 5: Audiogram shows on the right side low frequency conductive hearing loss with the typical air-bone gap.

Results: Two patients had complete disappearance of all symptoms. The third patient had significant improvement and retained minimal vertigo after surgery. There were no postoperative complications, except temporarily complaints of CSF hypotension in one patient. There were no reinterventions needed. Conductive hearing normalized in all patients in comparison with preoperative audiograms.

Conclusion: The subtemporal extradural approach with resurfacing of the dehiscence is safe and grateful technique to improve severe, disabling symptoms. It is in addition the only surgical technique to give possible improvement of the hearing loss.